

Cataract & Refractive Surgery TODAY

November/December 2014 • Volume 14, No. 11 • www.crstoday.com



BEST *of* 2014

THE YEAR IN REVIEW

The best that 2014 had to offer cataract and refractive surgeons and the top videos from Eyetube.net.

SURGICAL PEARLS | RESEARCH OR REVIEW ARTICLES/PRESENTATIONS | TECHNOLOGIES





Members of *CRST's* editorial board share their picks for the year's best surgical pearls, research, and technology.

BY GILLIAN McDERMOTT, MA, EDITOR-IN-CHIEF

In *Cataract & Refractive Surgery Today's* annual article, members of the publication's editorial board offer their choices for the best the year had to offer. Because this article went to press before 2015 began, any developments from the last weeks of 2014 will have been missed. Even so, the panel had much to say.

◆ BEST of 2014 ◆

SURGICAL PEARL

CORTICAL REMOVAL

For the third year in a row, a majority of the panel thought the top pearls dealt with cataract surgery.

Two ophthalmologists were impressed by advice on cortical cleanup. According to Jay S. Pepose, MD, PhD, of St. Louis, "The one-step continuous circular cortical aspiration technique, called 'hurricane cortical aspiration,' has the potential to improve this part of phacemulsification surgery. It offers benefits in both reduced surgical time and reduced traction on the zonular fibers

through better distribution of tractional forces, which may be of great benefit in patients with pseudoexfoliation or zonulopathy of other etiologies."¹

Humbly acknowledging that it might only be new to him, William I. Bond, MD, of Pekin, Illinois, nominated a tip from Anita Nevyas-Wallace, MD. "Like many (most) of the real pearls one gets at meetings, this one was given in the coffee area outside the actual presentations," Dr. Bond remarked. "When removing cortex after the nucleus is gone, move the tip of the I/A [handpiece] obliquely along the edge of the [capsulorhexis] rather than moving each piece straight to the center. This tends to mobilize much bigger pieces of cortex, the removal is much more smooth, and it incidentally usually removes the subincisional cortex during one of the sweeps. By obliquely, I mean move the I/A tip roughly parallel to the edge of the capsulorhexis rather than toward the center each time. For me, this cuts a minimum of 90 seconds off each and every case, and the removal is far easier and seems more controlled."

LASER CATARACT SURGERY

Los Angeles surgeon Robert K. Maloney selected advice from A. James Khodabakhsh, MD. Despite the open capsulorhexis, Dr. Maloney said, it is possible to effectively stain the anterior capsule with trypan blue after the laser portion of cataract surgery. "This is useful in cases where the surgeon has poor visibility or is worried about anterior capsular tags with the possibility of a radial tear," he explained.

Cathleen M. McCabe, MD, of Sarasota, Florida, prized a video presented by Vaishali Vasavada, MS, at the annual meeting of the American Society of Cataract and Refractive Surgery (ASCRS).² Dr. McCabe said that the video described "using 'femtodelineation' with a multiring cylinder pattern to improve safety in posterior polar cataracts." She also adjusts "the posterior gate of the lens fragmentation pattern to allow for sequential removal of segments of the nucleus in a manner that protects the fragile or compromised central posterior capsule during lens removal," she continued. "Also, increasing spot and layer separation settings decreases bubble size, resulting in less potential for increased intracapsular pressure due to gas bubble formation during femtosecond nuclear fragmentation."

ASTIGMATIC CORRECTION

Astigmatic correction during cataract surgery was an important topic in *CRST* this year as well as at major meetings. Mitchell A. Jackson, MD, of Lake Villa, Illinois, chose a tip from Jonathan Solomon, MD, on astigmatic incisions created with a femtosecond laser (Lensar Laser System; Lensar). Specifically, he said that nomogram adjustments decrease the arc radius from 4.5 to 4.3 mm for with-the-rule astigmatic incisions and from 5 to 4.5 mm for against-the-rule (ATR) astigmatic incisions to avoid arcus senilis. Dr. Jackson commented, "If the laser sees arcus, it will abort the [incisions'] creation, requiring manual conversion for these cuts. With this radius adjustment, ... this conversion to manual due to arcus is now avoided in over 90% of cases in my experience."

MORGAGNIAN CATARACT

Two panelists singled out a *CRST* article by Lisa Brothers Arbisser, MD, that appeared in our April edition.³

"Ophthalmologists in the Western world don't come across Morgagnian cataracts very often," noted Los Angeles surgeon Kevin M. Miller. "As a result, we don't have occasion to think of the things we would do differently. In this article, Lisa Arbisser nicely sum-

marized the unique features of these cataracts and what the ophthalmologist should do differently when planning their surgical care."

Chief Medical Editor Steven J. Dell, MD, of Austin, Texas, commented, "While some have advocated femtosecond laser capsulotomy in this situation, she advises against it, because the release of turbid lens material may block the laser and create an incomplete capsulotomy. Dr. Arbisser describes a very helpful technique of staining the capsule, depressing the capsule with a viscoadaptive [ophthalmic viscosurgical device], and creating a small capsulorhexis, which may be enlarged later in the case."

RUPTURED CAPSULE

For Dr. Arbisser herself, the year's best pearl dealt with avoiding a complication. In her experience, she said, the posterior capsule is most likely to rupture during removal of the final fragments of a dense nucleus, owing to surge while the capsule is unprotected. "Excellent evasive maneuvers include stepping down fluid parameters for those last pieces and using the chopper to hold back the [posterior chamber]," she remarked. "Nevertheless, rarely, the capsule can come up around the chopper and be dinged. Brian Little, FRCS, FRCOphth, suggests that, rather than turning the chopper and holding it below the phaco tip, one remove the chopper entirely during ultrasound of the final fragment. Since the paracentesis is larger than the [chopper's] shaft, it is a prime place for subtle leak of [balanced salt solution], leading to chamber shallowing and instability. Removing the chopper then allows the paracentesis lips to close and the chamber to remain more stable, preventing [posterior capsular rupture]."

NO HYDRODELINEATION

Randall J. Olson, MD, learned this year that Robert Cionni, MD, is no longer performing hydrodelineation, either during laser cataract surgery or prechop. Dr. Olson reported that Dr. Cionni is able to remove all of the segments more cleanly in one action and that an epinuclear bowl is then unnecessary. Dr. Olson said that his own experience with the approach has been positive thus far.

IOL EXCHANGE

Mark Packer, MD, chose "a safe and solid suggestion" by Narang et al.⁴ "[They] described the procedure of placing a new IOL in the capsular bag before cutting and explanting the old IOL, which is first viscodissected free and allowed to rest in the distal anterior chamber," he said.



MICROINVASIVE GLAUCOMA SURGERY

Microinvasive glaucoma surgery (MIGS) has been a hot topic at ophthalmological meetings all year, and the FDA's future clearance of more MIGS devices will only stoke surgeons' interest. Chief Medical Editor Eric D. Donnenfeld, MD, heralded advice from Ike Ahmed, MD, on the use of the iStent Trabecular Micro-Bypass Stent (Glaukos). "Ike places the iStent first, prior to cataract surgery, when the cornea is the clearest and the anterior chamber is quiet. The iStent-first technique has made visualization of the angle clearer for me and the procedure easier. In addition, I like performing my cataract surgery from above, so after placing the iStent, I can move the microscope to my preferred surgical location."

ENDOTHELIAL KERATOPLASTY

Not everyone surveyed focused on cataract surgery. Three panelists chose pearls for endothelial keratoplasty. Kenneth A. Beckman, MD, of Westerville, Ohio, thanked Jodi Luchs, MD, for advice shared this summer. "I had [a] patient with aniridia that had a previous failed DSEK [Descemet stripping endothelial keratoplasty], previous posterior vitrectomy, and previous sutured [posterior chamber IOL], all done by other surgeons. I needed to repeat his DSEK. I was concerned that maintaining a good air fill in a patient like this would be difficult, and therefore, he is at increased risk for a graft detachment. Due to his aniridia, previous vitrectomy, and [compromised] barrier to the posterior segment, he then is at risk of a detached graft[']s falling into the posterior segment. Dr. Luchs described a technique of suturing the DSEK graft in place to decrease the risk of graft detachment. Even if the graft were to detach, the risk of [its] falling into the posterior segment would be eliminated by the suture. Fortunately, the graft did not detach and remains clear."

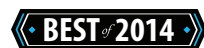Kathryn M. Hatch, MD, of Waltham, Massachusetts, commented that, "in Descemet membrane endothelial keratoplasty [DMEK], we traditionally have relied on the tissue[']s scrolling endothelium out and expect it to behave as it is 'supposed to.' Orientation can be difficult with tight scrolls, preexisting corneal edema, floppy grafts, or a shallow [anterior chamber]. The 'S' stamp is an inexpensive, intuitive, reassuring way to ensure proper graft orientation. ... Dr. Peter Veldman's work with Drs. Michael Straiko and Mark Terry at the Devers Eye Institute showed only 1.5% endothelial cell loss from the use of the S stamp.⁵ The use of the S stamp can reliably eliminate one of the causes of primary graft failure, upside-down DMEK grafts."

For William J. Lahners, MD, of Sarasota, Florida, the year's best pearl concerned something overlooked dur-

ing routine surgery. Although generally quite satisfied with his results with Descemet stripping automated endothelial keratoplasty, Dr. Lahners wondered if he could learn to reduce his dislocation/refloat rate. Then, during a presentation at the 2014 annual meeting of the ASCRS, he listened to Sonia Yoo, MD, describe "a method of polishing the posterior recipient [corneal] stroma at the periphery of the intended graft location," he said. "This technique she attributes to Dr. Mark Terry, and she recommends the eponymous Terry scraper for the technique. Since adopting the technique, I have noticed a decrease in my incidence of dislocations and refloats. The best pearls are the ones where we have to change our technique only a small amount to produce powerful results."

INTRAOPERATIVE ABERROMETRY

Most intriguing to George O. Waring IV, MD, of Charleston, South Carolina, was a suggestion by William F. Wiley, MD, to perform intraoperative aberrometry before and during enhancement procedures executed with corneal surface ablation. According to Dr. Waring, this approach has the potential to isolate the role of epithelial hyperplasia in refractive enhancements and phototherapeutic keratectomy.



RESEARCH OR REVIEW ARTICLE/PRESENTATION

ASTIGMATIC CORRECTION

For this category, three panelists were most impressed by work in the area of astigmatic correction. Dr. Hatch selected an article showing that toric IOLs can effectively address astigmatism after penetrating keratoplasty or deep anterior lamellar keratoplasty.⁶ Mean refractive spherical equivalent and refractive astigmatism decreased significantly in these eyes, she said. Moreover, she added, mean uncorrected and corrected distance visual acuity improved in this cohort of 26 eyes. According to Dr. Hatch, these data allow surgeons to consider using toric IOLs nontraditionally.

Dr. McCabe selected a video presentation by Graham Barrett, MD, at this year's ASCRS symposium.⁷ She noted that Dr. Barrett's new toric calculator and the Barrett Universal II IOL Formula are available on the Asia-Pacific Association of Cataract and Refractive Surgeons website and that the toric formula is also available on the ASCRS website. The new formula "increases the predictive power for toric IOL power calculations by factoring

in effective lens position,” Dr. McCabe said. In his video, she added, Dr. Barrett reported “improved accuracy even when compared to formulas using the Baylor adjustment for posterior corneal curvature or using measured posterior corneal curvature with the Pentacam [Comprehensive Eye Scanner (Oculus)]. Using the Barrett calculator, 72% of eyes are within 0.50 D of predicted [postoperative] cylinder, a significant improvement over all other methods.”

In the same vein, Douglas Koch, MD, was the source of Dr. Lahners’ favorite research this year. “In his presentation at the 2014 ASCRS annual meeting, [Dr. Koch] showed his data and a sample nomogram to compensate for the contribution of posterior corneal curvature in our astigmatic results,”⁸ Dr. Lahners related. “The posterior cornea contributes ATR astigmatism in the vast majority of patients, and if this is not compensated for, we will tend to overcorrect our [with-the-rule] astigmatism patients and undercorrect our ATR astigmatism patients. This and other work by Dr. Graham Barrett have contributed to our ability to hit the target in our astigmatic refractive IOL cases.”

THE OCULAR SURFACE

Two panelists nominated a review article on the ocular surface by Edward C. Lai, MD, and Christopher E. Starr, MD, that was published in the January edition of *CRST*.⁹ Dr. Donnenfeld commented, “One of the greatest improvements in cataract surgical outcomes has been the understanding by surgeons of the importance of the ocular surface.” He stated that the article provided “a comprehensive overview of all the pearls a clinician needs to adopt to improve quality of vision after cataract surgery.”

Jai G. Parekh, MD, MBA, of Woodland Park, New Jersey, agreed. He said that the article conveys the necessity of treating dry eye disease around the time of cataract surgery.

LENS EXTRACTION

Two panelists focused on lens extraction but chose very different articles. Dr. Arbisser’s interest lay in the intersection of cataract and glaucoma surgery. “In my opinion, the next decade will merge cataract surgery with glaucoma in the way that the last decade blended cataract and cornea with the refractive explosion,” she explained. “Now that we have MIGS and ab interno approaches are becoming the focus of glaucoma surgery and research, the bread and butter of cataract surgeons will begin to include these options.”

Dr. Arbisser said she believes that an article by Brown et al¹⁰ “is the progenitor of the decade to

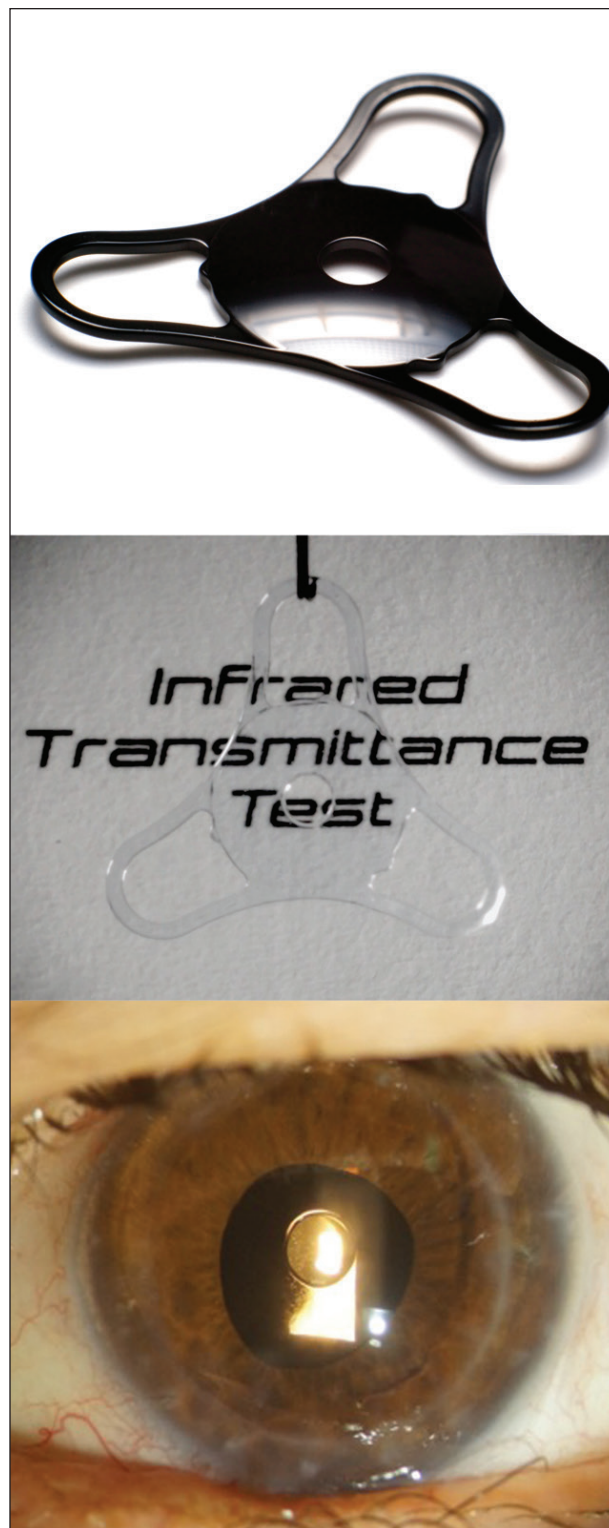


Figure. This foldable black acrylic pinhole implant is opaque to white light (top) but transparent to infrared wavelengths (middle). The device in an eye with a corneal transplant and irregular astigmatism (bottom).

(Courtesy of Claudio Tindade, MD)

come. It is high time that cataract surgeons realize all the tools at their discretion when advising glaucoma patients about the timing of cataract removal. Even clear lens exchange in narrow-angle glaucoma should become mainstream in my opinion. [Articles] such as this one are important, not only in morphing surgeons' therapeutic choices, but also in helping third-party payers to see their current pennywise and pound-foolish policies are antiquated."

Unlike Dr. Arbisser's, Dr. Bond's selection did not relate to MIGS. Rather, he voted for a presentation by Dr. Waring on "the concept of dysfunctional lens syndrome and the proper way for patients, and for us, to consider lens extraction for many long-term postrefractive surgical situations, particularly in patients over [the age of] 50."¹¹ Dr. Bond called the concept "extremely practical ... and beneficial to patients."

IMPLANT

Cincinnati surgeon Michael E. Snyder, MD, selected an ASCRS presentation by Claudio Trindade, MD, on his "ingenious pinhole implant," which is being developed by Morcher (Figure).¹² Dr. Snyder said that the implant "is intended to improve the corrected and uncorrected vision for patients with irregular astigmatism, for example, patients with corneal scars or post full-thickness corneal transplants. It may also benefit patients with regular ametropic refractive errors or perhaps even presbyopia. The device is made of a black foldable acrylic polymer, which is opaque to white light but completely transparent to infrared [light]. Accordingly, the fundus can be easily viewed with an indocyanine green fundus camera, and slit-lamp biomicroscopy can be achieved by modifying the slit-lamp light source and attaching an infrared sensor array."

LASIK

According to Dr. Waring, the best article of 2014 was the first to track epithelial changes after LASIK and to correlate these changes with corneal power.¹³

Dr. Dell picked a prospective, randomized, contralateral eye study that directly compared wavefront-guided to wavefront-optimized LASIK treatments.¹⁴ "Many prior studies compare current versions of one technology with an older version of another technology, but this study examined state-of-the-art versions of each," Dr. Dell remarked. "Manche and colleagues showed excellent results with both platforms, with wavefront-guided treatments showing slightly superior residual refractive error, uncorrected distance acuity, and contrast sensitivity."

The detailed results of a study by Ianchulev et al drew Dr. Packer's praise. He stated that the researchers used intraoperative aberrometry to improve the refractive outcomes of cataract surgery in patients with a history of LASIK.¹⁵ The ORA System (Alcon) significantly outperformed the surgeons' best choice, Haigis L method, and Shammas method, Dr. Packer said.

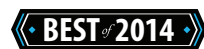CORNEAL TRANSPLANTATION

Corneal transplantation was the subject of the year's top research, Dr. Pepose asserted. As an advance beyond Descemet stripping automated endothelial keratoplasty and DMEK, he said, "the use of Rho-associated kinase inhibitors that modulate cultured corneal endothelial cell adhesion properties enabled transplantation of an endothelial cell suspension without the use of a carrier. [Rho-associated kinase] inhibitors may also alter endothelial cell differentiation and proliferation and could play a potential role independently as a medical treatment of Fuchs dystrophy pending the results of further research."¹⁶

KEY OPINION LEADERS

Dr. Miller looked beyond the OR and the clinic when he chose a review by Calvin W. Roberts, MD, and Paul Misiti from *CRST*'s February issue.¹⁷

"American medicine entered a new era of public reporting this year," Dr. Miller stated. "[The Centers for Medicare & Medicaid Services] releases Medicare payments to providers on public websites. Industry is required to report the consulting and investigator fees paid to physicians under the [Physician Payments] Sunshine Act. With this as background, and adding industry's desire to control costs and extract better value from its consultants, Cal Roberts and Paul Misiti in their article do a nice job defining what makes for a good key opinion leader."



TECHNOLOGY

TOPOGRAPHY

Both Dr. Packer and Dr. Jackson nominated new functionality on the Cassini (i-Optics) as the best technology of 2014. Dr. Packer highlighted the topographer's use of "a unique [light-emitting diode] array to measure the anterior corneal surface with extreme precision. This year's model adds the capability for posterior corneal astigmatism measurement."

Dr. Jackson was impressed by the device's ability to provide "total corneal astigmatism analysis, account-

ing for the effect of posterior corneal astigmatism published by Douglas Koch, MD, in 2013.¹⁸ Having this information will allow for [the] adjustment of toric IOL power, as recommended in Doug Koch's papers. Secondly, the iris registration software will be linked with Lensar's femtosecond laser system to allow for toric axis guidance at the time of cataract surgery to avoid conjunctival marking of the patient on the day of surgery."

DIAGNOSTICS

Dr. Parekh was most excited about InflammADry (Rapid Pathogen Screening). Approved by the FDA late last year, the technology came to market in 2014, and Dr. Parekh incorporated it into his preoperative assessment of patients for ocular surface disease and inflammation prior to cataract surgery. Dr. Parekh stated that the test is affordable and easy for his staff to use. He added, "The surgeon gets the result and may alter his/her approach to the patient, not only preoperatively by delaying the surgery and priming the ocular surface, but also postoperatively by dictating the most efficient and safest pharmacologic regimen."

AXIAL ALIGNMENT

"Sometimes, the simplest, least expensive technology is best," commented Dr. Arbisser. She nominated what she described as a homemade, easily applied strip for axial measurement devised by Valerie and David George for use with the Haag-Streit BM900 series slit lamp.¹⁹ "For years, I have been 'ball parking' the final axis of implanted toric lenses by having the phoropter nearby and aping the axis when viewing at the slit lamp," she said. "When the refractive outcome of the toric lens misses its mark, however, an accurate axis must be plugged into astigmatism-fix online calculators to formulate a remediation plan. The Georges describe their simple method for scanning a scale, printing and cutting it out, and taping it to the slit lamp to nail the exact axis at which an implanted toric [IOL] sits."

According to Dr. Arbisser, the Georges compared their measurement with the strip to images made with the Galilei G2 corneal analyzer (Ziemer Ophthalmic Systems) and found it to be precise.

PHACOEMULSIFICATION

Dr. Olson was clear about his selection. "Hands down, the forced/monitored infusion system of the Centurion Vision System [Alcon] is the biggest thing I have seen," he said. "The chamber stability is incredible, and I strongly vote for this as the technology breakthrough of the year!"

LASER CATARACT SURGERY

Dr. McCabe voted for the whole package. She chose Alcon's Laser Refractive Cataract Suite, which introduced the company's Verion Image Guided System. She stated that the suite's integration of "preoperative biometry [Lenstar; Haag-Streit]; preoperative imaging of the patient's eye; preoperative planning with advanced IOL formulae and the ability to manipulate lens choice, incision location, and limbal relaxing incisions; integration with [a] femtosecond laser to automatically adjust for cyclorotation; and intraoperative guidance for multifocal centration and toric alignment [is] together a major step forward in minimizing inaccuracies that can occur at each step of the process and compound, affecting outcomes."

Dr. McCabe anticipates that Alcon's acquisition of the ORA System will allow another big leap forward: the "integration of real-time refractive feedback for fine-tuning the operative plan and maximizing outcomes. It will be these kinds of integrated systems with preoperative imaging and measurements linked to the femtosecond [laser] surgical plan and intraoperative guidance utilizing active aberrometry that will move refractive cataract surgery to the next level."

IMPLANTS

Looking abroad, Dr. Pepose called extended-range-of-vision IOLs the year's technological breakthrough. The Tecnis Symphony IOL (Abbott Medical Optics) received the CE Mark in June 2014. Dr. Pepose provided details on this category of lenses.

"One approach is via the use of diffractive optics to provide seamless through focus from distance to intermediate and near," he said. "These IOLs provide a continuous range of vision and, in contrast to multifocal IOLs, lack distinct light energy foci peaked at distance and near. By not having multiple images simultaneously cast on the retina, this approach may reduce photic phenomena. Other distinctive features of this IOL include both the offset of corneal spherical aberration as well as reduced longitudinal chromatic aberration, which serve to enhance image quality, offsetting the reduction due to the diffractive component."

Dr. Pepose described the Tecnis Symphony IOL as having a "biconvex, wavefront-designed, anterior aspheric surface and a posterior achromatic diffractive surface to enhance contrast sensitivity with echelette features [extending] the range of vision."

TOPOGRAPHY-GUIDED LASIK

For Dr. Lahners, the greatest technological advance was the availability this year of topography-guided

LASIK," following the FDA's approval of the procedure using the WaveLight Eye-Q excimer laser in 2013. He explained that the Topolyzer (Alcon) samples the cornea at 22,000 locations versus 168 with the WaveLight Analyzer (Alcon) or 240 with the WaveScan Wavefront System (Abbott Medical Optics). Moreover, unlike with wavefront-derived information, pupillary size does not limit the sample size, Dr. Lahners noted.

"Corneas with larger irregularities can also be more accurately analyzed using topographic information than wavefront data," he stated. "After a long wait, this technology is finally available in the United States, and we finally can utilize the powerful therapeutic advantages of topography-guided laser vision correction."

VISUALIZATION

Richard J. Mackool, MD, of Astoria, New York, voted for the 3D Sony Simplicity Videosystem (Sony Corporation of America). "The quality of the three-dimensional view is astounding, and in fact, it is every bit as good as the surgeon's view of the procedure through the operating microscope. We frequently have visiting surgeons at our ambulatory surgery center, and they have unanimously agreed with this appraisal. This technology is certain to dramatically facilitate both resident training and postresidency continuing medical education, and I believe it to be a virtual certainty that, within several years, we will witness the virtual replacement of two-dimensional videos with three-dimensional footage at major medical meetings."

NONSURGICAL PRESBYOPIC CORRECTION

Dr. Starr voted for the GlassesOff app, available for the iOS (Apple) and Android (Google). He described the technology as a "game changer when it comes to treating presbyopia. Based on the concepts of neuroadaptation and neuroplasticity, the app is a novel perceptual learning program, which trains the brain to rapidly recognize blurry near letters and words. The learned visual perception allows presbyopes to regain the ability to read without magnifiers. At age 43, I am getting close to being presbyopic, but now that this app is available, I'm a lot less concerned about it." ■

Lisa Brothers Arbisser, MD, holds an emeritus position at Eye Surgeons Associates in Bettendorf, Iowa. Dr. Arbisser is also an adjunct associate professor at the John A. Moran Eye Center of the University of Utah in Salt Lake City. She acknowledged no financial interest in the products or companies she mentioned. Dr. Arbisser may be reached at (563) 343-8896; drlisa@arbisser.com.



Kenneth A. Beckman, MD, is the director of corneal services at Comprehensive EyeCare of Central Ohio in Westerville, Ohio, and he is a clinical assistant professor of ophthalmology at The Ohio State University in Columbus, Ohio. Dr. Beckman may be reached at (614) 890-5692; kenbeckman22@aol.com.



William I. Bond, MD, is a cataract and refractive surgeon at Bond Eye Associates and an assistant clinical professor at the University of Illinois Medical School, both in Peoria, Illinois. Dr. Bond may be reached at pekineye@yahoo.com.



Steven J. Dell, MD, is the director of refractive and corneal surgery for Texan Eye in Austin. Dr. Dell may be reached at (512) 327-7000.



Eric D. Donnenfeld, MD, is a professor of ophthalmology at NYU and a trustee of Dartmouth Medical School in Hanover, New Hampshire. He acknowledged no financial interest in the product or company he mentioned. Dr. Donnenfeld may be reached at (516) 766-2519; ericdonnenfeld@gmail.com.



Kathryn M. Hatch, MD, is a member of the faculty in ophthalmology at Harvard Medical School, Massachusetts Eye and Ear Infirmary Waltham. Dr. Hatch may be reached at (781) 890-1023; kmasselam@gmail.com.



Mitchell A. Jackson, MD, is the founder and director of Jacksoneye in Lake Villa, Illinois. He is a consultant to Bausch + Lomb, i-Optics, and Lensar. Dr. Jackson may be reached at (847) 356-0700; mjlaserdoc@msn.com.



William J. Lahners, MD, is the medical director and director of laser vision services at Center for Sight in Sarasota, Florida. He is a consultant to Abbott Medical Optics, Alcon, and Bausch + Lomb. Dr. Lahners may be reached at (941) 925-2020; wjlahners@centerforsight.net.



Richard J. Mackool, MD, is the director of the Mackool Eye Institute and Laser Center in Astoria, New York. He acknowledged no financial interest in the product or company he mentioned. Dr. Mackool may be reached at (718) 728-3400, ext 256; mackooleye@aol.com.



Robert K. Maloney, MD, is the director of the Maloney Vision Institute in Los Angeles. Dr. Maloney may be reached at (310) 208-3937; info@maloneyvision.com.



Cathleen M. McCabe, MD, is a cataract and refractive specialist practicing at The Eye Associates in Bradenton and Sarasota, Florida. She is a consultant to and speaker for Alcon.



and Bausch + Lomb, and she is a speaker for Abbott Medical Optics. Dr. McCabe may be reached at (941) 792-2020; cmccabe13@hotmail.com.

Kevin M. Miller, MD, is the Kolokotronis professor of clinical ophthalmology, David Geffen School of Medicine at UCLA, Jules Stein Eye Institute. Dr. Miller may be reached at (310) 206-9951; kmiller@ucla.edu.



Randall J. Olson, MD, is chairman of the Department of Ophthalmology and Visual Sciences and CEO of the John A. Moran Eye Center at the University of Utah School of Medicine in Salt Lake City. He acknowledged no financial interest in the product or company he mentioned. Dr. Olson may be reached at (801) 585-6622; randallj.olson@hsc.utah.edu.



Mark Packer, MD, CPI, is president of Mark Packer MD Consulting. He is a consultant to Alcon, and he is a consultant to and holds equity in WaveTec Vision. Dr. Packer may be reached at mark@markpackerconsulting.com.



Jai G. Parekh, MD, MBA, is the managing partner at Brar-Parekh Eye Associates in Woodland Park, New Jersey, and chief of cornea and external diseases/chief of the Research Institute at St. Joseph's HealthCare System, located in Wayne/Paterson, New Jersey. Dr. Parekh is also a clinical associate professor of ophthalmology on the Cornea Service at the New York Eye & Ear Infirmary of Mt. Sinai/Icahn School of Medicine at Mt. Sinai in New York City. He acknowledged no financial interest in the product or company he mentioned. Dr. Parekh may be reached at (973) 785-2050; kerajai@gmail.com.



Jay S. Pepose, MD, PhD, is founder and director of the Pepose Vision Institute, Chesterfield, Missouri, and a professor of clinical ophthalmology and visual sciences at the Washington University School of Medicine in St. Louis. He is a consultant to Abbott Medical Optics and Bausch + Lomb. Dr. Pepose may be reached at (636) 728-0111; jpepose@peposevision.com.



Michael E. Snyder, MD, is on the Board of Directors at Cincinnati Eye Institute and is volunteer faculty at the University of Cincinnati. He acknowledged no financial interest in the product or company he mentioned. Dr. Snyder may be reached at (513) 984-5133; msnyder@cincinnatieye.com.



Christopher E. Starr, MD, is an associate professor of ophthalmology at Weill Cornell Medical College in New York and is the



director of the Refractive Surgery Service, director of the cornea, cataract, and refractive surgery fellowship, and director of ophthalmic education. A family member of his holds stock in GlassesOff. Dr. Starr may be reached at cestarr@med.cornell.edu.

George O. Waring IV, MD, is the director of refractive surgery and an assistant professor of ophthalmology at the Storm Eye Institute, Medical University of South Carolina, and adjunct assistant professor of bioengineering at Clemson University. Dr. Waring may be reached at waringg@muscc.edu.



1. Nakano CT, Motta AFP, Hida T, et al. Hurricane cortical aspiration technique: one-step continuous circular aspiration maneuver. *J Cataract Refract Surg.* 2014;40:514-516.
2. Vasavada V. Femto-delineation: posterior polar simplified. Video presented at: ASCRS/ASOA Symposium & Congress; April 25-29, 2014; Boston, MA.
3. Arbisser LB. Morgagnian cataract. *Cataract & Refractive Surgery Today.* April 2014;14(4):61-62. <http://bmctoday.net/crstoday/2014/04/article.asp?f=morgagnian-ataract>. Accessed October 22, 2014.
4. Narang P, Steinert R, Little B, Agarwal A. Intraocular lens scaffold to facilitate intraocular lens exchange. *J Cataract Refract Surg.* 2014;40:1403-1407.
5. Veldman PB, Mayko Z, Straiko MD, Terry MA. Descemet membrane endothelial keratoplasty: early complications and 6-month endothelial cell loss in a comparative series of unstamped and stromal sided S-stamped tissue in 101 consecutive cases. Paper presented at: AAO Annual Meeting; October 19, 2014; Chicago, IL.
6. Lockington D, Wang EF, Patel DV, et al. Effectiveness of cataract phacoemulsification with toric intraocular lenses in addressing astigmatism after keratoplasty [published online ahead of print October 2, 2014]. *J Cataract Refract Surg.* doi:10.1016/j.jcrs.2014.03.025.
7. Barrett GD. Flight of the arrow—toric IOL power prediction. Video presented at: ASCRS/ASOA Symposium & Congress; April 25-29, 2014; Boston, MA.
8. Koch D. Posterior corneal astigmatism. Paper presented at: ASCRS/ASOA Symposium & Congress; April 25-29, 2014; Boston, MA.
9. Lai EG, Starr CE. Managing dry eye disease in cataract patients. *Cataract & Refractive Surgery Today.* January 2014;14(1):53-55. <http://bmctoday.net/crstoday/2014/01/article.asp?f=managing-dry-eye-disease-in-ataract-patients>. Accessed October 22, 2014.
10. Brown RH, Zhong L, Lynch MG. Lens-based glaucoma surgery: using cataract surgery to reduce intraocular pressure. *J Cataract Refract Surg.* 2014; 40(8):1255-1262.
11. Waring G. RLE for dysfunctional lens syndrome is the future. Paper presented at: AECOS Summer Meeting; July 25, 2014; Deer Valley, UT.
12. Trindade CC. Managing irregular corneal astigmatism and pseudophakic presbyopia with novel small-aperture intraocular implant. Paper presented at: ASCRS/ASOA Symposium & Congress; April 25-29, 2014; Boston, MA.
13. Maia Rocha K, Krueger RR. Spectral-domain optical coherence tomography epithelial and flap thickness mapping in femtosecond laser-assisted in situ keratomileusis. *Am J Ophthalmol.* 2014;158(2):293-301.
14. He L, Liu A, Manche EE. Wavefront-guided versus wavefront-optimized laser in situ keratomileusis for patients with myopia: a prospective randomized contralateral eye study. *Am J Ophthalmol.* 2014;157(6):1170-1178.e1.
15. Ianchulev T, Hoffer KJ, Yoo SH, et al. Intraoperative refractive biometry for predicting intraocular lens power calculation after prior myopic refractive surgery. *Ophthalmology.* 2014;121:56-60.
16. Okumura N, Kinoshita S, Koizumi N. Cell-based approach for treatment of corneal endothelial dysfunction. *Cornea.* 2014;33(suppl 11):S37-S41.
17. Roberts CW, Misiti P. How to be a great KOL. *Cataract & Refractive Surgery Today.* February 2014;14(2):61-62. <http://bmctoday.net/crstoday/2014/02/article.asp?f=how-to-be-a-great-kol>. Accessed October 22, 2014.
18. Koch DD, Jenkins RB, Weikert MP, et al. Correcting astigmatism with toric intraocular lenses: effect of posterior corneal astigmatism. *J Cataract Refract Surg.* 2013;39(12):1803-1809.
19. George VE, George DS. Axis measurement strip for Haag-Streit BM900 series slitlamp. *J Cataract Refract Surg.* 2014;40(10):1584-1587.